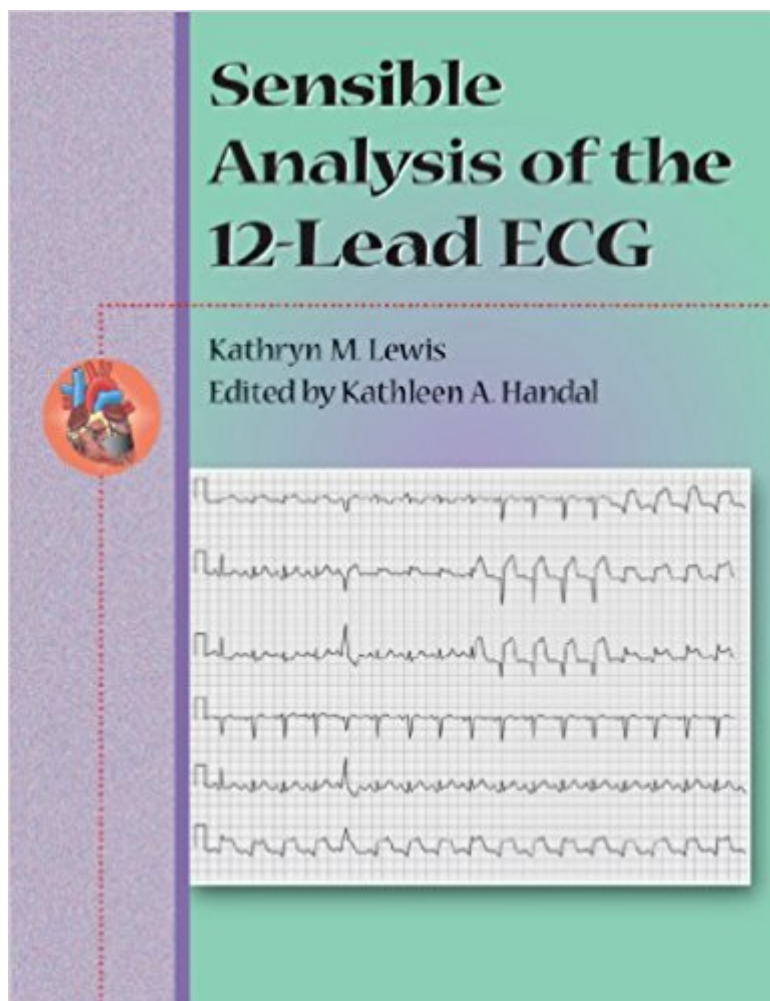


The book was found

# Sensible Analysis Of The 12-Lead ECG



## Synopsis

This text provides in-depth introduction to the analysis of the 12-lead electrocardiogram. It offers comprehensive review of cardiac anatomy and relates pathology to the ECG findings. Pathology of cardiac conduction as seen in 3-lead and 12-lead monitoring systems are presented in a practical manner to build confidence in this valuable diagnostic tool. There are self-assessment exercise for each chapter and an overall review section. An instructor supplement will accompany the text. The text reflects the U.S. DOT Paramedic and Intermediate Curricula.

## Book Information

Series: Sensible Analysis Of The 12-lead Ecg

Paperback: 275 pages

Publisher: Cengage Learning; 1 edition (January 26, 2000)

Language: English

ISBN-10: 0766805247

ISBN-13: 978-0766805248

Product Dimensions: 8.5 x 0.6 x 11 inches

Shipping Weight: 1.4 pounds (View shipping rates and policies)

Average Customer Review: Be the first to review this item

Best Sellers Rank: #2,949,545 in Books (See Top 100 in Books) #83 in [Books > Textbooks >](#)

[Medicine & Health Sciences > Reference > Instruments & Supplies](#) #131 in [Books > Medical](#)

[Books > Medicine > Reference > Instruments & Supplies](#) #451 in [Books > Textbooks >](#)

[Medicine & Health Sciences > Nursing > Clinical > Nurse & Patient](#)

## Customer Reviews

CHAPTER 1: The Heart's Conductive System. Introduction. The Electrical Conduction System. The SinusNode. The AV Junction. The Bundle Branch System. The Purkinje Fibers.

ELECTROPHYSIOLOGY OF THE HEART. The Phases of the Cardiac Cycle. Properties of the Specialized Cells. Pacemakers, Escape Rhythms, and Ectopic Foci. Summary. Self Assessment.

CHAPTER 2: Introduction. The ECG Leads: A Point of View. Limb Leads. Precordial (Chest) Leads. Monitoring the Posterior Surface of the Heart. MCL Leads. Hazards of Improper Placement of

Leads. Summary. Self Assessment. CHAPTER 3: Rate, Rhythm, and Wave Forms. Introduction.

Calculating Rhythm. Wave Forms, Complexes, and Intervals. Waves. The PR Interval. QRS

Complex. Segment. The T Wave. The QT Interval. The U Wave. Abnormal Wave Forms. Abnormal P Waves. Abnormal PR Interval. Abnormal QRS Complexes. Abnormal QT Interval. Abnormal U

Waves. Alterations in ECG Wave Forms. Drug-induced Changes on the ECG. Hyperkalemia. Hypokalemia. Hypercalcemia. Hypocalcemia. Low Voltage QRS. Pericarditis. Pericardial Effusion. Ventricular Aneurysm. Hypertrophic Cardiomyopathy (HCM). Increased Intracranial Pressure. Pulmonary Embolism. Summary. Self Evaluation. CHAPTER 4: Axis Determination and Implications. Introduction. Normal Axis. Axis Deviation. Right Axis Deviation. Left Axis Deviation. Calculation of Axis. Normal and Abnormal Values. The Lewis Circle. Summary . Self Assessment. CHAPTER 5: Sinus Rhythm and the Arrhythmias. Introduction. How to Look at and Analyze the Wave Forms. Labeling the ECG. How to Assess a Monitor Pattern. The Sinus Mechanisms. Sinus Tachycardia. Sinus Bradycardia. Sinus Arrhythmia. Sinus Arrest. Sinoatrial (SA) Block. The Junctional Mechanisms. Junctional Rhythm. Premature Junctional Complex. Accelerated Junctional Rhythm and Junctional Tachycardia. The Atrial Mechanisms. Premature Atrial Complex (PAC). Atrial Tachycardia. Supraventricular Tachycardia. Atrial Flutter. Atrial Fibrillation. The Ventricular Mechanisms. Characteristics of a Ventricular Ectopic. Narrow Complex PVCs. Variations in PVCs. Ventricular Tachycardia. Intermittent Ventricular Tachycardia. Polymorphic Ventricular Tachycardia. Ventricular Fibrillation. Ventricular Escape: Idioventricular Rhythm. Accelerated Idioventricular Rhythm. Aberrant Ventricular Conduction. Aystole. A Conduction Defects. Sinus Rhythm with First-Degree AV Block. Sinus with second degree AV Block, The Intermittent Conduction Defects. Second-degree AV Block, The Wenckebach Phenomenon aka Type I AV Block. Second Degree AV Block with Wide QRS complex (Type II). Second degree AV Block, AV Block with 2:1 Conduction as Fixed Rate Second Degree AV Block. Sinus with High-Grade (Advanced AV Block). Sinus with Complete AV Block. Arrhythmias Due to Abnormal Conduction Pathways. The ECG Wave Forms Affected by Preexcitation. Degrees of Preexcitation. Arrhythmias with Preexcitation. Lown-Gannong-Levine Syndrome. Wolff-Parkinson-White (WPW) Syndrome. Summary. Self Assessment. CHAPTER 6: Myocardial Perfusion Deficits and ECG Changes. Introduction. Coronary Artery Perfusion. Pathophysiology of Acute Myocardial Infarction. Consequences of Coronary Artery Occlusion. Monitoring of Myocardial Ischemia, Injury, and Necrosis on the ECG. Reflecting and Reciprocal Leads. Changes in Wave Forms. Inferior Wall (Diaphragmatic) Myocardial Infarction. Clinical Implications of Inferior Wall Myocardial Infarction. Anterior Wall and Anterior-Septal Myocardial Infarction. Clinical Implications for Anterior Wall Myocardial Infarction. Antero-Septal Myocardial Infarction. Anterolateral Myocardial Infarction. Lateral Wall Myocardial Infarction. Clinical Implications of Lateral Wall Myocardial Infarction. Posterior Wall Myocardial Infarction. Clinical Implications for Posterior Wall Myocardial Infarction. Right Ventricular Myocardial Infarction. Clinical Implications of Right Ventricular Wall Myocardial Infarction. Non-Q Wave Myocardial Infarction.

Pseudo Infarction Patterns. Early Repolarization. Non-classic ECG Presentation of Acute Myocardial Infarction. Continuous ST Segment Monitoring. Summary. Self Assessment. CHAPTER 7: Fascicular Block. Introduction. Arterial Perfusion to Bundle Branches. Normal Sequence of Ventricular Depolarization and the QRS Vector. Bundle Branch Block - ECG Changes. Right Bundle Branch Block (RRBB). Left Bundle Branch Block. Fascicular Blocks. Left Anterior Fascicular Block. Left Anterior Fascicular Block and RBBB. Left Anterior Fascicular Block and Myocardial Infarction. Left Posterior Fascicular Block. Complete Left Bundle Branch Block . Trifascicular Block. Summary. Self Assessment. CHAPTER 8: Chamber Enlargement and Hypertrophy. Introduction. Right Atrial Enlargement. Left Atrial Enlargement. Ventricular Hypertrophy. Right Ventricular Hypertrophy. Left Ventricular Hypertrophy. Ventricular Strain Pattern. Summary. Self Assessment.

Dr. Lewis is the President of KACEL, Inc. Professional and Community Education. She is also adjunct faculty within the Maricopa County Community College District where she is accredited to teach in all level of EMS courses and is an Examiner for the National Registry of EMTs. After serving as EMT/FSC Department Chair at Phoenix College since 1986, Dr. Lewis retired in 2005. During that time she was also a member of the Arizona EMS Council (Governor's Appointment), and member of the National EMS Curriculum Development Group. She has worked as a critical care nurse and educator, has authored several articles and contributed to texts on nursing care, education theory and techniques, as well as various cardiovascular topics. Dr. Lewis holds many industry affiliations and credentials, is an active RN and holds a BSN in nursing and a PhD in Education.

[Download to continue reading...](#)

12-Lead ECG: The Art Of Interpretation (Garcia, Introduction to 12-Lead ECG) Sensible Analysis of the 12-Lead ECG ECG Workout: Exercises in Arrhythmia Interpretation (Huff, ECG Workout) ECG Success: Exercises in ECG Interpretation EKG Interpretation: 24 Hours or Less to EASILY PASS the ECG Portion of the NCLEX! (EKG Book, ECG, NCLEX-RN Content Guide, Registered Nurse, Study Guide, ... Cardiology, Critical Care, Medical ebooks) EKG | ECG: For Beginners! - How To Easily Learn EKG Interpretation, Cardiac Dysrhythmias And Arrhythmias! (EKG Book, ECG, Medical ebooks) ECG Mastery: The Simplest Way to Learn the ECG EKG Interpretation: 24 Hours or Less to EASILY PASS the ECG Portion of the NCLEX! (EKG Book, ECG, NCLEX-RN Content Guide, Registered Nurse, Study ... Critical Care, Medical ebooks) (Volume 1) The 12-Lead ECG in Acute Coronary Syndromes - Text and Pocket Reference Package, 3e 12-Lead ECG for Acute and Critical Care Providers EKG: EKG Interpretation Made Easy: A Complete Step-By-Step Guide to

12-Lead EKG/ECG Interpretation & Arrhythmias (EKG Book, EKG Interpretation, NCLEX, NCLEX RN, NCLEX Review) 12-Lead ECG: The Art of Interpretation Introduction To 12-Lead ECG: The Art Of Interpretation Lead Sheet Bible: A Step-by-Step Guide to Writing Lead Sheets and Chord Charts (Private Lessons / Musicians Institute) Lead with Your Heart . . . Lessons from a Life with Horses: Finding Wholeness and Harmony at the End of a Lead Rope Lead and Lead Alloys: Properties and Technology (German Edition) The Doctors' Clinic 30 Program: A Sensible Approach to losing weight and keeping it off Sensible Cruising: The Thoreau Approach : A Philosophic and Practical Approach to Cruising Even the Odds: Sensible Risk-Taking in Business, Investing, and Life Vaccinations: A Thoughtful Parent's Guide: How to Make Safe, Sensible Decisions about the Risks, Benefits, and Alternatives

[Contact Us](#)

[DMCA](#)

[Privacy](#)

[FAQ & Help](#)